

Pfefferbaum A, Adalsteinsson E, Bell R, McBride W, Sullivan EV
Neuroscience Program, SRI International

Department of Electrical Engineering and Computer Science and Massachusetts Institute of Technology Harvard-MIT Division of Health, Sciences, Technology, Massachusetts Institute of Technology

Department of Psychiatry and Behavioral Sciences, Stanford University School of Medicine

Department of Psychiatry, Indiana University School of Medicine

Introduction: An animal model of voluntary alcohol consumption provides the opportunity to examine many aspects of human alcoholism which are difficult to control in the natural condition. For instance, in addition to the potential direct neurotoxic effects of alcohol are the effects of accompanying nutritional deficiency such as are seen in Wernicke's Encephalopathy, caused by thiamine deficiency. In human alcoholics Wernicke's Encephalopathy presents with characteristic neurological symptoms and radiological signs involving thalamus, mammillary nuclei, and inferior colliculi. Here we present quantitative, longitudinal brain MR analysis of a rat model of Wernicke's Encephalopathy conducted on a human 3T MR system.

Methods: We studied 18 mature male, alcohol-preferring P rats of Wistar stock, selectively bred to consume alcohol voluntarily [1,2]. Over the preceding year, 9 animals had been exposed to alcohol. The animals were then divided into 2 groups for a thiamine deficiency experiment. All received a thiamine deficient diet for 2 weeks; 10 also received intraperitoneal (IP) pyriethiamine, a thiamine antagonist; 8 served as controls and received thiamine supplementation IP.

MRI data were acquired on a 3T GE Signa human clinical scanner with standard product sequences [3] before and after the thiamine deficiency experiment. An 8-rung birdcage transmit/receive coil constructed from cylinders of clear plexiglass (2.5-in inner diameter, 6-in length) was used. Because this coil required substantially less RF power than standard human coils on this scanner, an RF attenuator, set at 15dB, was inserted between the pre- and power RF amplifiers during the scans. With this configuration, the standard prescan tuning software automatically determined the transmission and receiver gains, linear shims, and center frequency. The animals were held in an MR invisible structure, which provided support for the RF coil and a nose cone for delivery of isoflurane anesthesia (2-3%) and oxygen (~2 liters/min). Rectal temperature and oxygen saturation from a hind limb were monitored throughout the experiment. Heating was provided by pre-warmed bags of saline solution placed under the animal tray and from a temperature-controlled water-heating blanket placed over the animal.

A dual-echo spin-echo protocol was graphically prescribed to cover the entire rat brain (3.3cm) in 66 coronal slices (TE1/2=16/50 ms, TR=5s, FOV=60mm, 256x256 pixel resolution, 0.5mm slice thickness, 22min acquisition time) and run three times for improved SNR. The resulting native spatial resolution was 234x234x500 μm . Total session time was ~80min, excluding animal preparation.

Results and Discussion: Brain images were transferred to a workstation where the three MRI runs were averaged, aligned by selecting the midpoint of the brain on a central, coronal slice, rotated in-plane to make the interhemispheric fissure vertical, and expanded three-fold in-plane with a sinc interpolation to produce in-plane pixel dimensions of 78 μm .

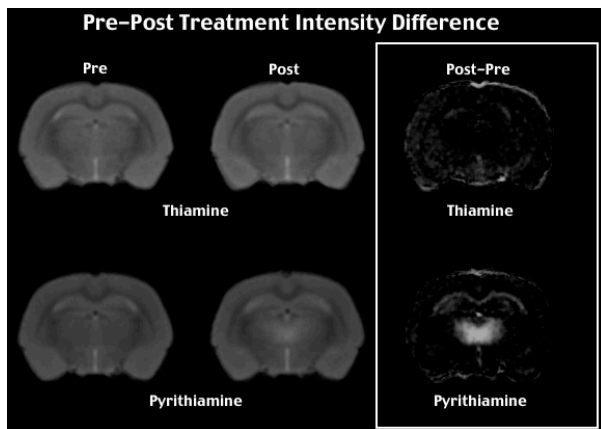


Fig. 1. Pre- post-treatment with pyriethiamine. Difference projection images (right) identify a bilateral thalamic region of high signal intensity.

Manual measurement revealed significantly enlarged ventricles in the pyriethiamine-treated (PT) compared with the thiamine-treated (TT) animals ($t=2.50$, $p<.025$). To investigate parenchymal effects of thiamine deficiency, all brains were interpolated to isotropic voxels and aligned to a common space (12-parameter affine [4]). Grand average brain images were constructed for early- and late-echo data for each group separately for pre- and post-treatment conditions, followed by creation of subtraction images: post-treatment minus pre-treatment. Display of the resultant late-echo subtraction images (Fig. 1) revealed three regions of high signal intensity, identified on the early echo data as located in the thalamus, inferior colliculus, and medial mammillary body nucleus [5]. These regions were manually identified on the grand average data, and projections of the circumscribed regions to each animal were used for quantification. Irrespective of prior alcohol exposure, the pre-post image intensities (Fig. 2) were significantly greater in the PT than TT group for all three regions on both early-echo (thalamus $p=.0001$, colliculus $p=.0001$, mammillary $p=.0001$) and late-echo data (thalamus $p<.0025$, colliculus $p=.0001$, mammillary $p=.03$).

Two-point T2 images were also constructed and pre-post differences examined; T2 was significantly longer in the thalamus and inferior colliculus (thalamus $p<.02$, colliculus $p<.002$, mammillary $p=.45$).

Conclusion: The ventricular results are consistent with previously reported data in a Sprague-Dawley rat model [6]. The thiamine-induced parenchymal changes, with increased T2 suggesting increase inter- and extracellular fluid accumulation, concur with human clinical radiological signs of Wernicke's Encephalopathy. The results further demonstrate the feasibility and sensitivity of using human 3T MR systems to examine rodent brain neuropathology longitudinally in vivo.

Support: AA13521 (INIA), AA13522 (INIA), AA05965

References:

1. Li T-K et al (1979) Drug Alc Dep 4:45.
2. McBride WJ, Li T-K (1998) Critical Reviews in Neurobiology 12:339-69.
3. Pfefferbaum A, Adalsteinsson E, Sullivan EV (2004) JMRI 20:779-785.
4. Woods R et al. (1998) Journal of Computer Assisted Tomography 22: 139-152.
5. Paxinos G, Watson C (1998) The Rat Brain in Stereotaxic Coordinates, Academic Press, San Diego, CA.
6. Pentney R et al. (1993) Alcoholism: Clin Exp Res, 17:1301-1308.

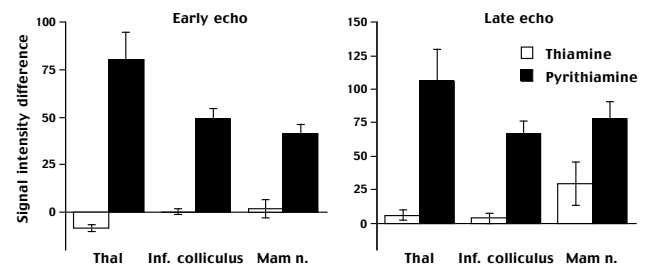


Fig. 2. Signal intensity differences on early- and late-echo MRI data in brain regions, which developed lesions following a thiamine deficiency regime.